

360 DEGREE SUBANNULAR TYMPANOPLASTY: A RETROSPECTIVE STUDYKuldeep Moras¹, Savita Lasarado², Rahul Shivaraj³, Anita Aramani⁴, George Pinto⁵**HOW TO CITE THIS ARTICLE:**

Kuldeep Moras, Savita Lasarado, Rahul Shivaraj, Anita Aramani, George Pinto. "360 Degree Subannular Tympanoplasty: A Retrospective Study". Journal of Evolution of Medical and Dental Sciences 2015; Vol. 4, Issue 32, April 20; Page: 5455-5461, DOI: 10.14260/jemds/2015/800

ABSTRACT: OBJECTIVE OF THE STUDY: To study the efficacy of underlay tympanoplasty by elevating the annulus by 360 degrees. **SUBJECTS AND METHODS:** Two hundred patients with chronic otitis media, tubotympanic disease, inactive stage who underwent tympanoplasty by the above technique between the years 2009 to 2013 were selected for the study as and when they were admitted. All the patients were followed up for 6 months following surgery. Any complications like secondary infection, wound dehiscence, granulations, were looked for and treated appropriately. Status of the neotympanum was evaluated at the end of 3 months. Any anterior blunting, medialisation or lateralisation of the graft was noted. Any residual perforation was considered as failure. Hearing was evaluated in all patients with an intact neotympanum. **RESULTS:** Our study showed an overall success rate of 96% as far as graft uptake was concerned. Hearing improvement was seen in 93% of our patients. 6 patients had complete air bone gap closure, 49 had AB gap of 10db or less, 131 had AB gap of 11-20db. 14 patients had no improvement in hearing. Overall hearing improvement was seen in 93% of our patients. **CONCLUSION:** In conclusion 360 degree sub-annular tympanoplasty is a efficient technique of tympanoplasty with very good results.

KEYWORDS: Subannular, underlay, tympanoplasty, 360 degrees.

INTRODUCTION: Tympanoplasty has come a long way after it was first introduced by Wullstein and Zollner in the early 1950's. It is done by various techniques of underlay, overlay and interlay. The underlay technique has become popular over the years the world over because of its distinctive advantages, viz- ease of graft placement, prevention of lateralization of graft and better take up rate. There is no uniformity in any of the techniques, various centers in the world have standardized their own way of doing it. Even in India, different centres do it differently, although most of the techniques being underlay. In this study we have studied the efficacy of placing the graft by completely elevating the annulus and pars flaccida by 360°. The technique, its benefits and pitfalls have been described.

MATERIALS AND METHODS: The present study: 360° Underlay Tympanoplasty: A Retrospective Study of 200 Cases was conducted between the years 2009 to 2013. Data was sourced from 200 patients who underwent tympanoplasty for chronic suppurative otitis media (CSOM), tubotympanic disease (TTD). The patients were selected serialwise as and when they were admitted for surgery. The ears which were dry at the time of surgery were taken up for this study. Patients were in the age group of 16- 65 years. Patients with comorbidities like diabetes mellitus, cardiac disease were excluded from this study. Patients undergoing revision surgery were also excluded from this study. Patients with all ossicles intact and mobile were included in the study.

METHOD OF COLLECTION OF DATA: Two hundred patients who underwent tympanoplasty for a CSOM, tubotympanic disease, dry ear were included in this study. The patients were admitted one day prior to surgery. Routine blood investigations- haemoglobin, random blood sugar, serum urea,

ORIGINAL ARTICLE

creatinine, HIV, HbsAg and HCV were done. ECG and chest X-ray were done in patients above 40 years of age. A Puretone Audiometry was done pre-operatively. All patients were started on Amoxicillin-Clavulunate 50mg/kg body weight the day before surgery.

PROCEDURE: All patients were operated under general anaesthesia. After painting and draping, a post auricular incision 5mm behind the post aural sulcus is made and temporalis fascia graft harvested. A V-shaped incision is given over the mastoid periosteum and mastoid cortex is exposed. A posterior meatotomy is done just below the Spine of Henle, from 6 O' clock position to 12 O' clock position. The pinna is retracted forward with the help of ribbon gauze and a mastoid retractor is placed. The fat in the skin of the postero-superior aspect of external auditory canal is debulked and a small release incision given at about the 12 O'clock position. This gives a little more space for better visualization of the TM perforation. Now the margins of the perforation are freshened. Next, the posterior meatotomy incision is extended anterosuperiorly upto 10 O'clock position in the left ear or 2 o'clock position in the right ear (Fig. 1) and the entire tympanomeatal flap is elevated till the annulus.

Any bony canal overhang is drilled away using a diamond burr, which was done in majority of our cases in order to get a unobstructed view of entire perforation and the annulus. As the elevation of the flap precedes medially complete annulus was elevated by 270° degree from the bony annulus. The entire flap is now pushed forwards, and separated from the handle of malleus and its lateral process, along with the pars flaccida. Anterosuperiorly the Eustachian tube orifice is identified. This completes the entire elevation of the annulus and pars flaccida, hereby achieving a 360° degree elevation medially (Fig. 2). The entire flap is now attached superiorly by a triangular area between the 10 O'clock and 12 O'clock position laterally in the left ear, and 12 o'clock to 2 o'clock position laterally in the right ear. The apex of this triangle is about 2-3 mm lateral to the notch of Rivinus (Fig. 3). The vitality of the flap is maintained by the blood vessels going through the tympano-squamous suture line, superiorly.

Once the middle ear is inspected for the ossicular integrity, the dried temporalis fascia graft is placed. It is maneuvered behind the tympanomeatal flap towards the anterior canal wall. Now the canal flap is pushed back and the fascia graft is pulled on the anterior canal wall. The entire canal skin flap is placed back into its original position (Fig. 4). Now the posterior aspect of this assembly is reflected forwards and the middle ear is packed with gel foam soaked in neomycin, polymixin B and hydrocortisone (Neosporin H). Initial few pieces of gel foam about 4-5 are placed into the eustachian tube orifice, just to make sure the graft does not fall or retract into the eustachian tube orifice as there can be chances of a residual perforation in the antero-superior quadrant. The flap and graft assembly is put back and fine adjustments made and the graft placement is checked all around. The same medicated gel foam is placed lateral to the graft in the bony canal.

The postaural incision is closed by mattress sutures using 2-0 Ethilon in a single layer. Finally the outer external auditory canal is packed with gel foam smeared with neomycin, polymixin-B Ointment (Neosporin). Outer mastoid dressing is applied. The dressing is changed the next day and the patient discharged. Antibiotics (amox-clav), analgesics, antihistamines and multivitamins are continued for 2 weeks. Suture removal is done on the 7th post-operative day and the patient is asked to instill Neomycin, Polymixin-B, Hydrocortisone (Neosporin H) ear drops for 2 weeks.

ORIGINAL ARTICLE

The outer gelfoam is suctioned after 2 weeks and the ear drops are continued for 2 more weeks. On the next follow up that is 4 weeks after surgery all the gelfoam is suctioned and the neotympanum inspected. Any signs of infection, granulations are looked for and treated appropriately. All the patients are asked to come for a regular follow-up every 2 weeks. A pure tone audiogram is done at the end of 3 months and the hearing compared.

RESULTS:

Male	103
Female	97

Table 1: Number of cases

<20	21-30	31-40	41-50	51-60	>60
26	87	39	32	10	6

Table 2: Age Distribution of the patients

A total of 200 cases were selected for the study. Of the 200 patients 103 (51.5%) were males and 97 (48.5%) were females. A male preponderance was noticed in this study. It was found that majority of patients who underwent surgery were in their 3rd decade of life.

Canalplasty	161
Septoplasty	6
FESS	3
Adenoidectomy	3

Table 3: Concurrent procedures performed

Most of the patients had an anterior and inferior overhang. Concurrent procedures including septoplasty, FESS, and adenoidectomy were done in 6, 3 and 3 patients respectively in same sitting.

SIZE OF PERFORATION	NO. OF PATIENTS	PERCENTAGE
Small	39	19.5%
Medium	93	46.5%
Large/ Subtotal	68	34%

Table 4: Size of perforation

Of the total 200 cases, majority of them (46.5%) had a medium central perforation.

PRE-OP HEARING LOSS: 120 patients had mild hearing loss and 72 patients had moderate hearing loss. Moderately severe hearing loss was seen in 18 patients.

Perforation	Total	Complete A-B gap closure	10db or less	10db-20 db	20db or more	No. Imp
Small	39	4	17	9	4	5
	19.5%	10.3%	43.6%	23.1%	10.2%	12.8%
Medium	93	2	25	37	24	5
	46.5%	2.15%	26.8%	39.7%	25.8%	5.4%
Large	68	0	7	23	34	4
	34%	0	10.3%	33.8%	50%	5.8%
Total	200	6	49	69	62	14
	100%	3%	24.5%	34.5%	31%	7%

Table 5: Post-Operative Air Bone Gap Results

SUCCESS RATE: Our study showed an overall success rate of 96% as far as graft uptake was concerned. 8 patients (4%) were found to have a residual perforation, out of which 4 patients were smokers who started smoking immediately after discharge from the hospital. Overall hearing improvement was seen in 93% of our patients.

POST-OP COMPLICATIONS: Two patients started having continuous ear discharge after surgery, the culture and sensitivity of which grew pseudomonas which was resistant to all oral antibiotics. Blunting of the anterior tympanomeatal angle was seen in 6 patients. Intratympanic epithelial pearl formation was seen in 2 patients.

DISCUSSION: Various grafting techniques have been described in the past. There have been many modifications and variations of the technique of tympanoplasty. Primrose WJ et al described their techniques of closing the anterior marginal perforation, wherein a small tag was fashioned anteriorly and later pulled through a small tunnel under the anterior-superior annulus.¹

Palva described the surgical treatment of CSOM by means of Myringoplasty and Tympanoplasty.² His underlay "swinging door" technique was successful in 97% of the ears. He also came across 3 rigid footplates in his series of 225 patients. Palva's "swinging door" tympanoplasty was modified and reported by several otologic surgeons including Glasscock, Fisch, Smyth and Pennington. The basic technique involves the elevation of superiorly based and inferiorly based canal skin flaps, or "swinging doors". Schwaber MK reported a success rate of 95% with his study.³ Our study yielded a success rate of 96%, as far as graft uptake was concerned.

A similar study with almost a similar technique conducted by Mokhtarinejad F et al showed a success rate of 97%.⁴ They also showed that underlay tympanoplasty with elevation of annulus away from the sulcus tympanicus anteriorly did not result in blunting and lateralization of the graft. However, blunting of the anterior tympanomeatal angle was seen in 9 patients in the study. Kartush J.M et al study on "Over-Under Tympanoplasty, wherein the graft was placed over the malleus and under the annulus, similar to our technique, reported late perforations in 12 patients out of 120 who underwent surgery.⁵

In a comparative study done by Singh M et al, 93.3% success rate was seen in both underlay and overlay techniques.⁶ Medio-Lateral Tympanoplasty for anterior or subtotal perforation done by

ORIGINAL ARTICLE

Jung TT et al also has a success rate of 97%⁷. Out of 100 cases, 3 failed because of secondary infection. Overall success rate of 88% was seen in a study done by Vartiainen E et al.⁸

Hearing improvement was seen in 93% of our patients. 6 patients had complete AB gap closure, 49 had AB gap of 10db or less, 131 had AB gap of 11-20db. 14 patients had no improvement in hearing. Singh M et al had a hearing gain of 92.8% in the underlay group of patients⁶. 70% of the patients had a hearing improvement of 0-40db in Jung et al's study.⁷ Hearing gain of 10-30db was achieved in 95% of the cases in a study by Mishra P et al.⁹ AB gap within 10db was achieved in 61% and within 10db in 87% of the patients in Vartiainen E et al's study.⁸

Epithelial pearls were seen in 2 patients 3 months after surgery. Although they did not have any post-op complaints, they are on regular follow up. Vartiainen E et al reported 3 cases of post-op cholesteatoma in their series of 404 cases.⁸ Intra-tympanic membrane cholesteatoma after tympanoplasty was observed in 9 patients (0.8%) in Nejadkazem M, et al's study.¹⁰ They were asymptomatic and detected during routine follow up examination 1-2 years after surgery. Their common location was near the umbo. However in our series, 1 was seen in the pars flaccid area, another one in the region of umbo, may be because of insufficient removal of residual squamous epithelium from the handle of malleus. Persistent ear discharge was seen in 2 patients whose ears were dry at the time of surgery. Jung TT et al attributed their 3 cases of failure to post-op infections.⁷ Rigid footplate was seen in 2 patients in our series. Palva T reported a rigid footplate in 3 out of 225 of his cases.²

Blunting of anterior tympano-meatal angle was seen in 6 patients (3%).² However Mokhtarinejad F et al did not see blunting or lateralisation in their study of tympanoplasty, technique of which was similar to our technique. Canalplasty was done in majority of our cases (80.5%) in order to obtain a 360° view of the annulus which is helpful for placement of the graft particularly in the anterior segment. Vijendra H et al in their study have shown that canalplasty gives a 9db additional gain in hearing.¹¹

CONCLUSION: In conclusion 360° sub-annular tympanoplasty is a efficient technique of tympanoplasty with very good results.

REFERENCES:

1. Primrose WJ, Kerr AG. The anterior marginal perforation. *Clin Otolaryngol Allied Sci.* 1986 Jun; 11 (3) 175-6.
2. Palva T. Surgical treatment of chronic middle ear disease: Myringoplasty and tympanoplasty. *Acta Otolaryngol.* 1987 Sept-Oct; 104 (3-4): 279-84.
3. Schwaber MK. Postauricular undersurface tympanic membrane grafting: some modifications of "swinging door" technique. *Otolaryngol Head Neck Surg.* 1986 Sep; 95 (2): 182-7.
4. Mokhtarinejad F, Okhovat SA, Barzegar F. Surgical and hearing results of the circumferential subannular grafting technique in tympanoplasty: a randomized clinical study. *Am J Otolaryngol.* 2012 Jan-Feb; 33 (1): 75-9.
5. Kartush JM, Michaelides EM, Becavarovski Z, LaRouere MJ. Over-under tympanoplasty. *Laryngoscope* 2002 May; 112 (5): 802-7.
6. Singh M, Rai A, Bandyopadhyay S, Gupta SC. Comparative study of the underlay and overlay techniques of myringoplasty in large and subtotal perforations of the tympanic membrane. *J Laryngol Otol.* 2003 Jun; 117 (6): 444-8.

ORIGINAL ARTICLE

7. Jung TT, Park SK. Mediolateral graft tympanoplasty for anterior or subtotal tympanic membrane perforation. Otolaryngol Head Neck Surg. 2005 Apr; 132 (4): 532-6.
8. Vartianen E, Nuutinen J. Success and pitfalls in myringoplasty: follow-up study of 404 cases. Am J Otol. 1993 May; 14 (3): 301-5.
9. Mishra P, Sonkhya N, Mathur N. Prospective study of 100 cases of underlay tympanoplasty with superiorly based circumferential flap for subtotal perforations. Indian Journal of Otolaryngology and Head and Neck Surgery. 2007 Sep; 59 (3): 225-8.
10. Nejadkazem M, Totonchi J, Naderpour M, Lenarz M. Intratympanic membrane cholesteatoma after tympanoplasty with the underlay technique. Arch Otolaryngol Head Neck Surg. 2008 May; 134 (5): 501-2.
11. Vijayendra H, Ittop CJ, Sangeetha R. Comparative study of hearing improvement in type 1 tympanoplasty with and without canalplasty. Indian Journal of Otolaryngology and Head and Neck Surgery 2008 Oct-Dec; 60 (4): 341-344.

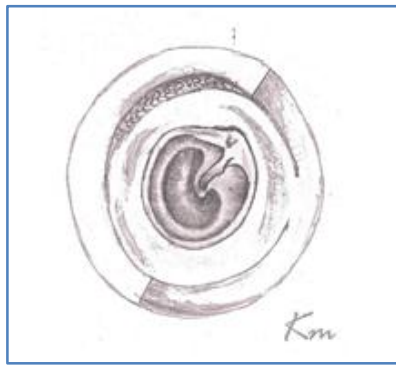


Figure 1: Canal skin incisions as described in the text

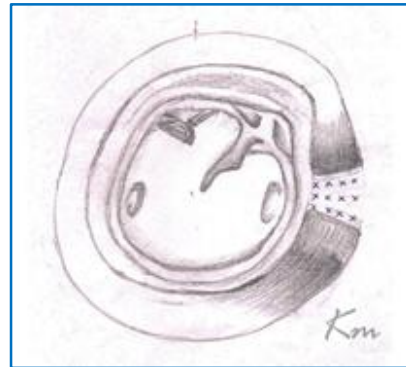


Figure 2: Complete elevation of the tympanomeatal flap from the annulus

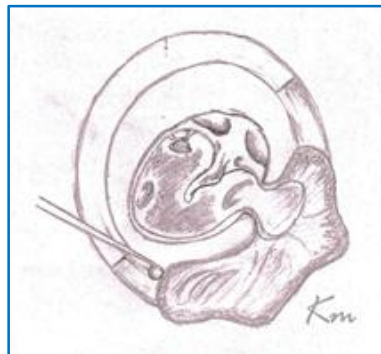

Fig. 3: This figure shows attachment of the tympanomeatal flap between the 1 O'clock and 3 O'clock positions

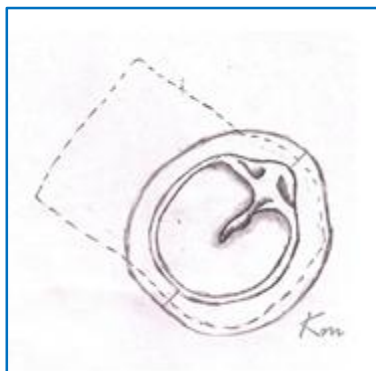


Figure 4: Final placement of the graft

AUTHORS:

1. Kuldeep Moras
2. Savita Lasarado
3. Rahul Shivaraj
4. Anita Aramani
5. George Pinto

PARTICULARS OF CONTRIBUTORS:

1. Associate Professor, Department of ENT, Father Muller Medical College.
2. Senior Resident, Department of ENT, Father Muller Medical College.
3. Post Graduate, Department of ENT, Father Muller Medical College.

FINANCIAL OR OTHER

COMPETING INTERESTS: None

4. Senior Resident, Department of ENT, Father Muller Medical College.
5. Professor, Department of ENT, Father Muller Medical College.

NAME ADDRESS EMAIL ID OF THE CORRESPONDING AUTHOR:

Dr. Rahul Shivaraj
Post Graduate,
Department of ENT,
Father Muller Medical College,
Kankanady, Mangalore-575002.
E-mail: rahulshivaraj@gmail.com

Date of Submission: 07/12/2014.
Date of Peer Review: 08/12/2014.
Date of Acceptance: 08/04/2015.
Date of Publishing: 17/04/2015.